

# RE-DISCOVERING DR. VODDER'S MLD

## EFFECT OF MLD FOR NON-LYMPHEDEMA CONDITIONS

KAZUE GILL  
MLD TRAINING CENTER  
JAPAN

# Of the Whole World's Population -

12% suffer from migraine

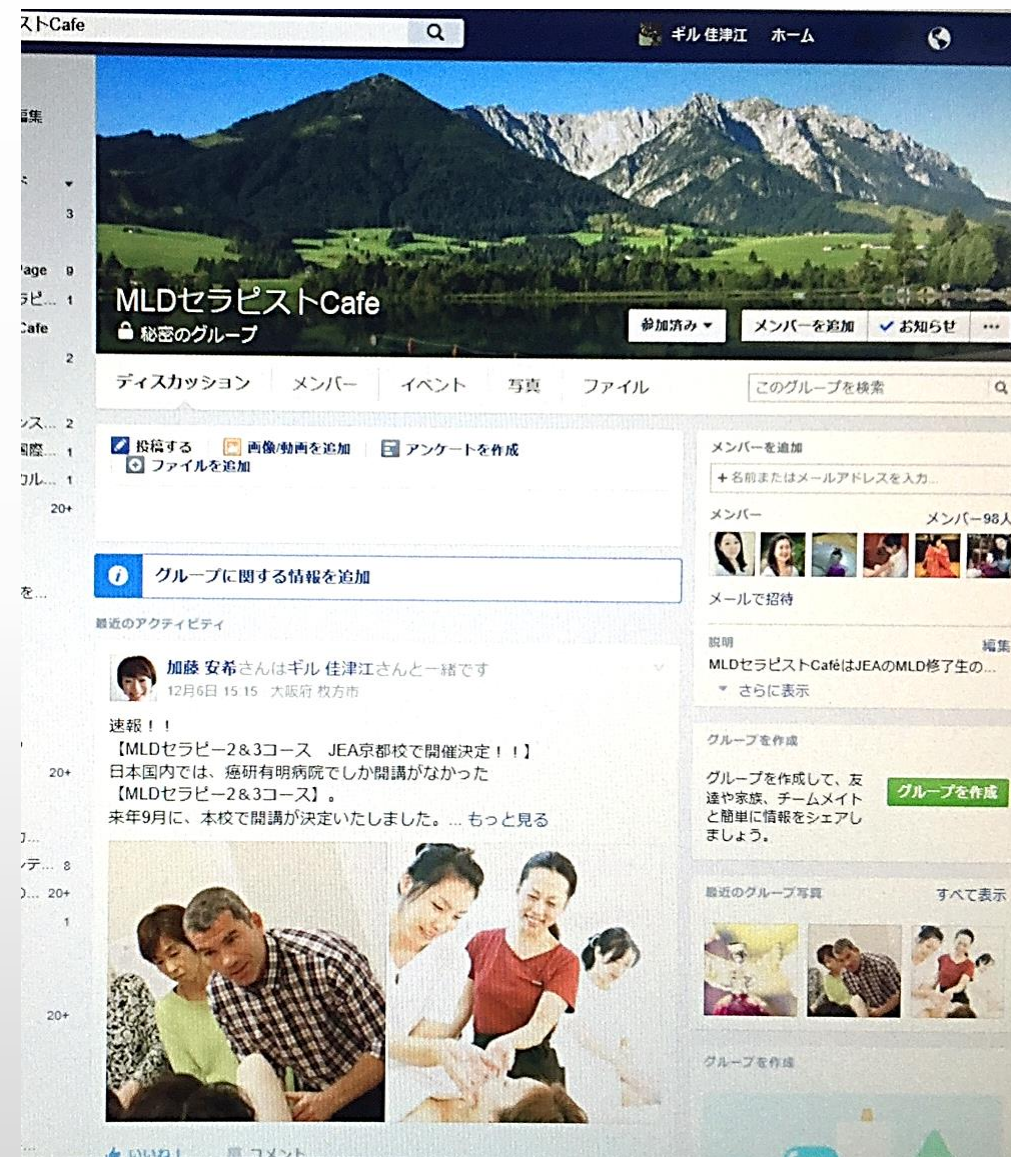5~10% suffer from atopic dermatitis

12% suffer from sinusitis



*“He palpated swollen lymph nodes in the necks of patients suffering from skin blemishes, migraines, and sinusitis. “*

*Dr. Vodder's Manual Lymph Drainage: A Practical Guide*



MLD Therapist Café on Facebook is a forum where Vodder MLD therapists can:

- Share case studies.
  - Ask for advice regarding MLD treatments.
  - Report interesting results and get feedback.
- Discover possible new indications for MLD
- Deepen our understanding of what MLD is doing to our body and mind
- Give incentives to therapists to try MLD for all sorts of conditions.

# CASE STUDIES BY JAPANESE THERAPISTS



# Trauma to the Eye in an accident during surfing

Therapist: Tomoko Takaike (occupation: nurse)      30/7/2014

## Patient:

Male, 46 years old (occupation: medical doctor)

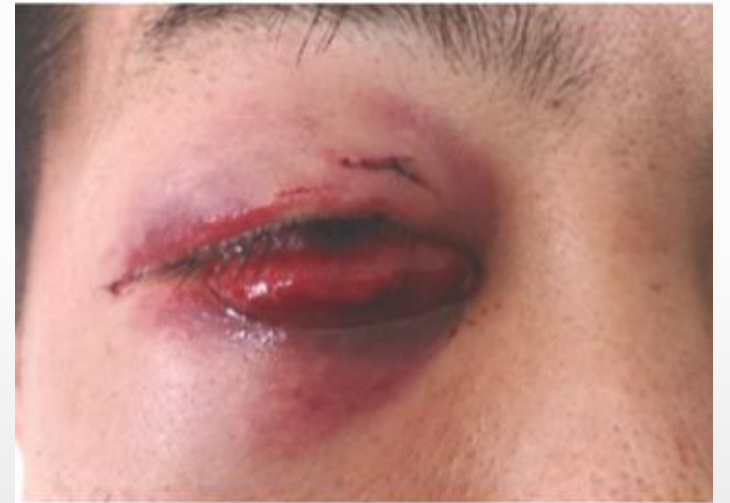★ An eye injury caused by accident.

His surf board hit his right eye during surfing.

No injury to the eye ball itself.

2 to 3 small cuts on the upper eye-lid which needed stitches.

Internal bleeding in the tissues around the eye.



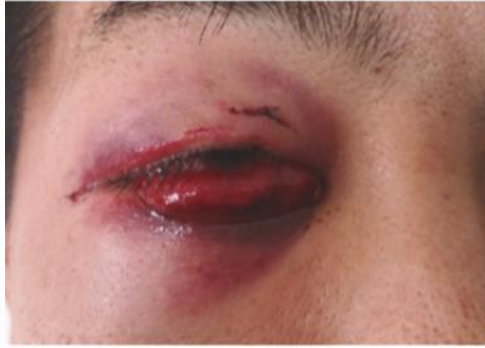## Main complaints:

- Double vision
- Headache and severe pain
- Nausea and dizziness
- Dilation of the pupil
- Sursumvergence and restriction of the right eye movement
- Swelling of the right side of the face and in particular around the right eye.

## Medication:

- Prednisolone (steroid) for five days
- Flomox (antibiotic), Loxoprofen (anti-inflammatory, analgesic) for seven days
- Ophthalmic drugs : Bronuck(NSAID), Tarivid, Vegamox (antimicrobial),  
Rinderon (steroid)

Day 2

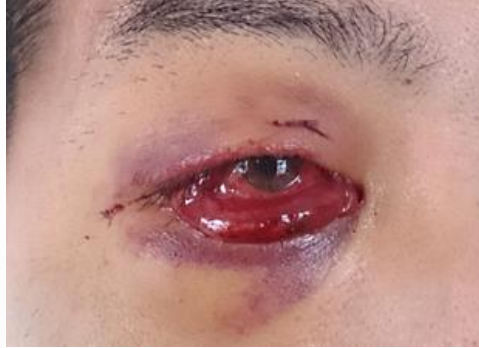

**1<sup>st</sup> treatment**

Duration: 70 minutes  
Neck 30  
Face 20  
Neck 20

Full facial on the unharmed side. The immediate area of the injury was avoided. Stationary circles inferior to the eye.

Day 4

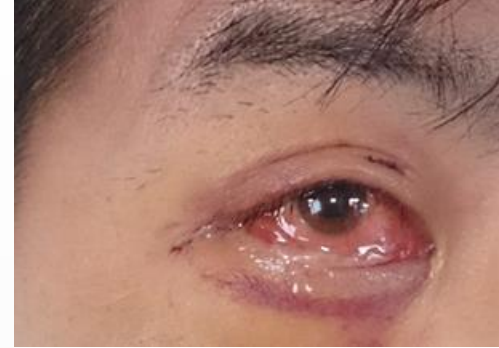

**4<sup>th</sup> & 5<sup>th</sup> treatments**

<AM>  
Duration: 45 minutes  
Similar treatment to the 1<sup>st</sup> treatment.

<PM >  
Duration: 70 minutes  
intensive work on the nose and ears, plus soft palate for short time. The surrounding of injured eye was worked on carefully.

Day 6

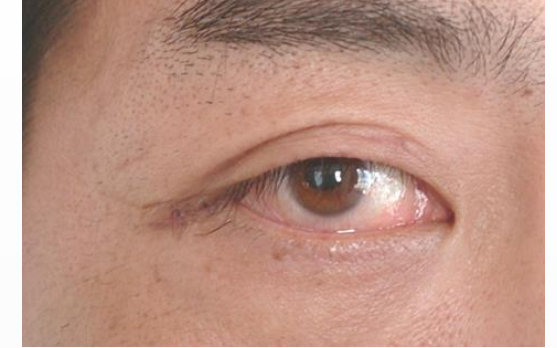

**6<sup>th</sup> treatment**

Duration: 70 minutes  
Neck 20  
Face 45  
Neck 5

Similar treatment to the last one. The inflammation of the conjunctiva was reduced.

Day 18

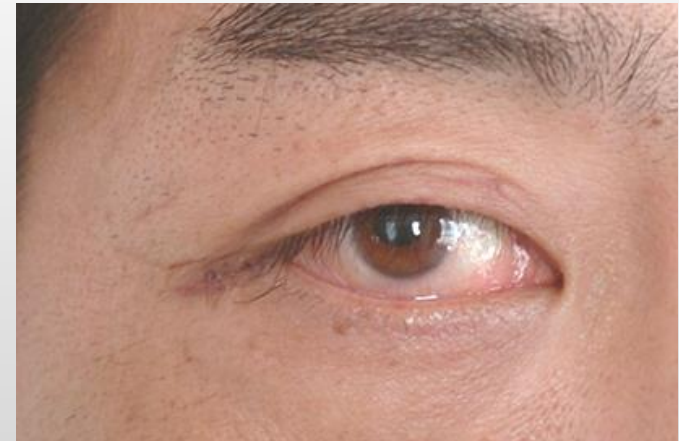


**11<sup>th</sup> treatment**

Duration: 50 minutes  
Neck 10  
Face 35  
Neck 5

## The result

- Externally the eye and the face look almost back to normal.
- The hematoma around the eye has cleared.
- Double vision, dizziness and headache ameliorated, but have still not completely disappeared.





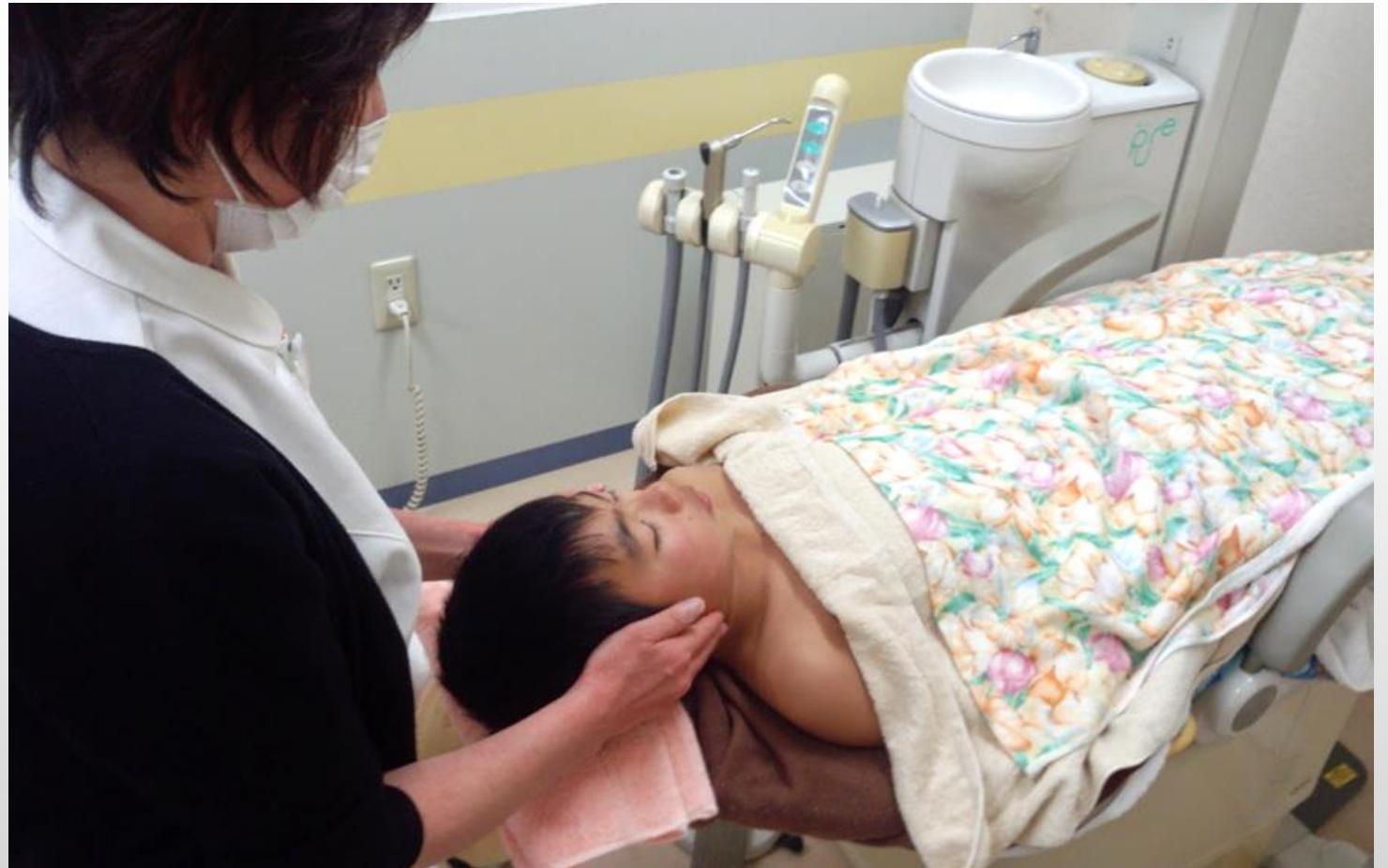# The effect of MLD in this case study

- Pain reduction : the pain was so strong in spite of using medicine, it prevented him from sleeping at night . During every treatment, the patient fell asleep.
- Reduction of swelling
- Reduction of hematoma : The delay in the reduction of hematoma could have left him with permanent damage to the optic nerve

# Therapist: Kunimi Aoyama (dental hygienist)

188 treatments between Dec. 2014 and Sep. 2016

- \* Sinusitis
- \* Hay fever
- \* Atopic dermatitis
- \* Eczema
- \* Restless legs syndrome
- \* Tinnitus
- \* Painful neck
- \* Headache
- \* Temporomandibular joint disorder
- \* Tenosynovitis
- \* Period pain
- \* Infarction of spinal cord



Patient: Male, age 11, dental patient

Condition: **Chronic sinusitis (blocked and runny nose and itchiness)**

Medical care: Visiting otolaryngology doctor once a week for the last 6 months.

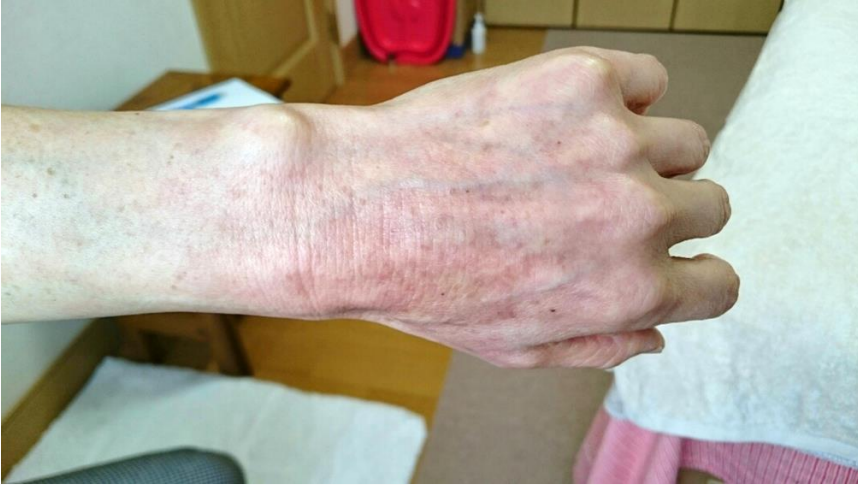Medication: no oral medication. Inhalation and nebulizer treatment

After the 1<sup>st</sup> treatment (1<sup>st</sup> Dec. 2014)

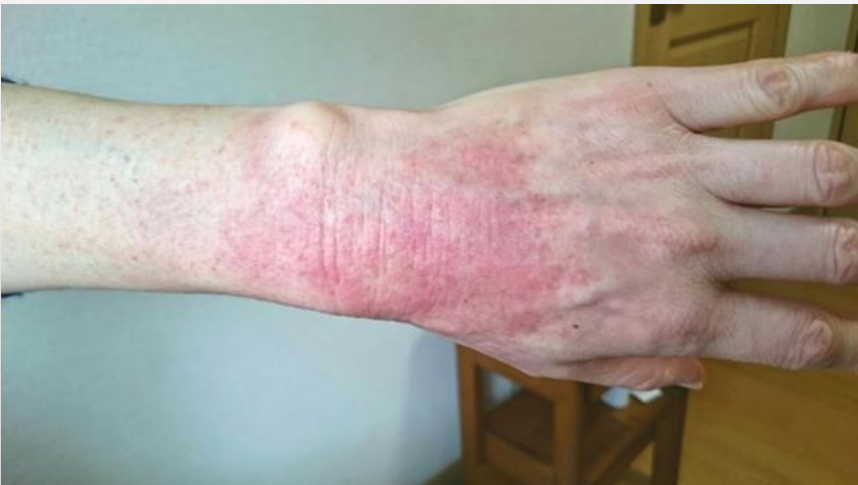- Snoring at night stopped
- Blowing nose decreased

treatment	date	Duration of treatment	0-10 NRS (numerical rating scale)
1 <sup>st</sup>	1/12/2014	43 min. (neck 18, face 25)	10
2 <sup>nd</sup>	3/12/2014	46 min. (neck 18, face 28)	
3 <sup>rd</sup>	4/12/2014	47 min. (neck 19, face 25, palate 3)	3
4 <sup>th</sup>	11/12/2014	53 min. (neck 19, face 25, ear 4, palate 6)	3
5 <sup>th</sup>	18/12/2014	50 min. (neck 15, face 25, ear 5, palate 5)	2 to 3
6 <sup>th</sup>	25/12/2014	50 min. (neck 15, face 25, ear 5, palate 5)	1 to 2

22 Jan. 1<sup>st</sup> treatment



6 Feb. 3<sup>rd</sup> treatment

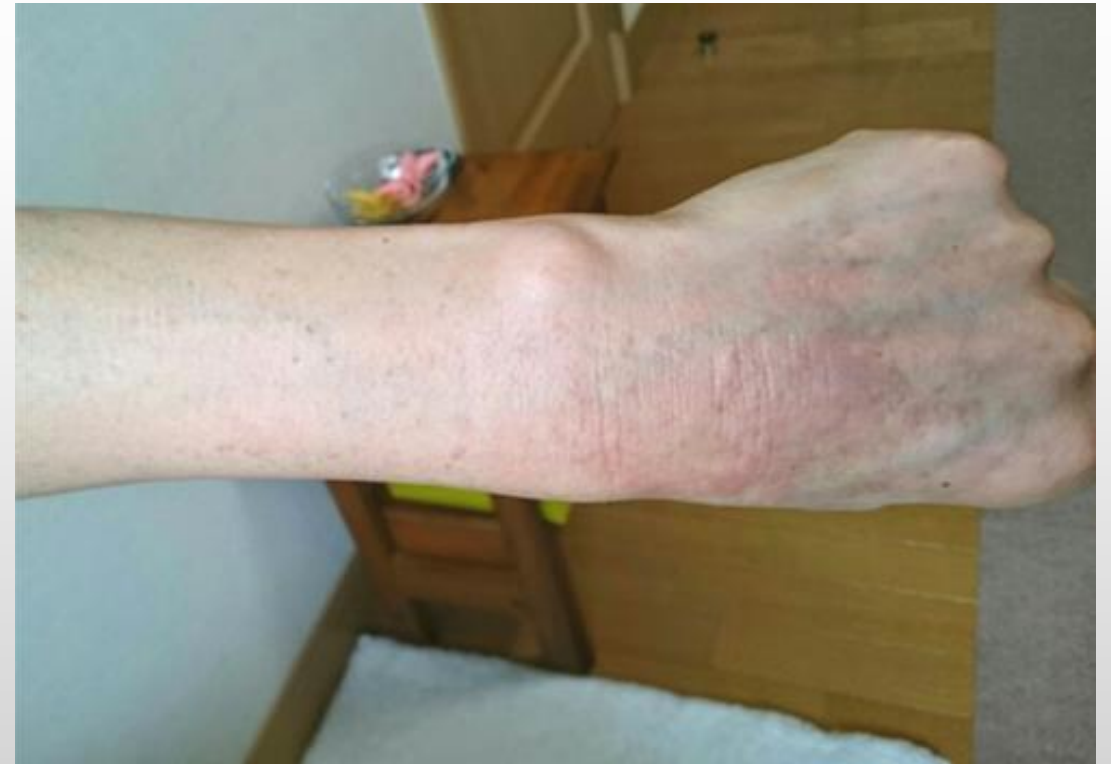

Female 53 years old

Condition: Eczema

Complaints: Inflammation and itchiness

8 Mar. 8<sup>th</sup> treatment



Therapist: Mika Mune (massage therapist)

Client: Male, age 68

Main complaints:

- 1) Chronic rhinitis (sneezing, itchy eyes, dripping nose for many years)
- 2) Polyp in the throat after catching cold two months ago  
(inflammation and loss of voice).
- 3) Tinnitus (the left ear for 2 months)

Duration of case study: 18 months, 1/week (120 min.)

Treatment: neck, face(incl. oral), head, back, abdomen

Case study report: August 2015

Chronic rhinitis:

➡ dripping nose significantly reduced 10 ➡ 2 (NRS)

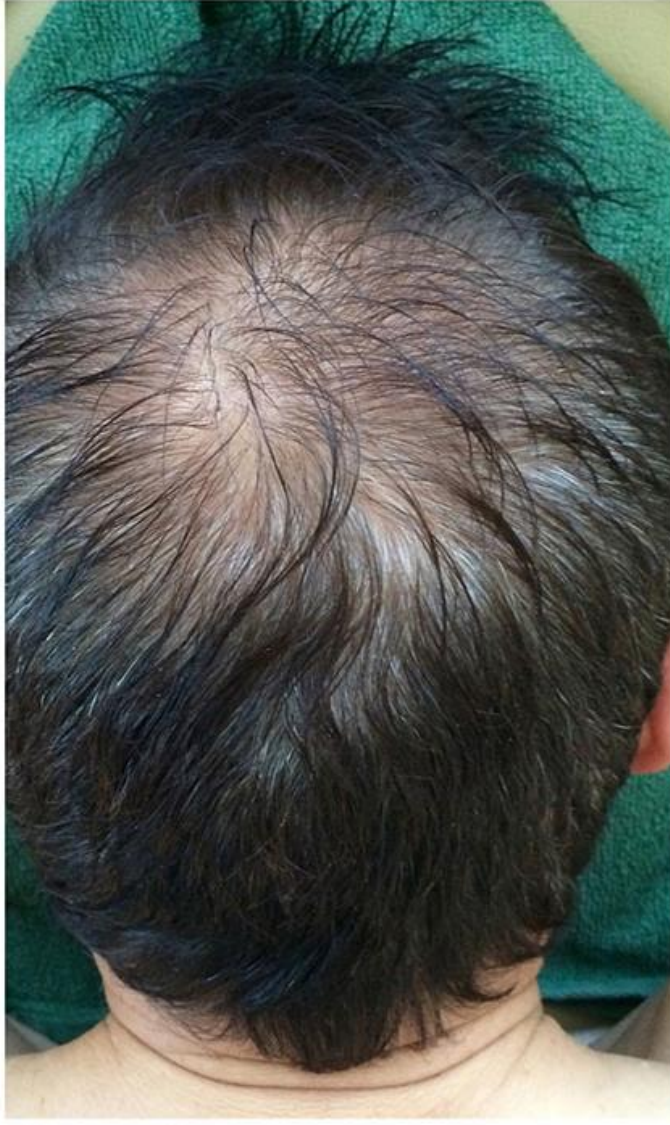Polyp in the throat:

➡ got his voice back the following day after the 1<sup>st</sup> treatment

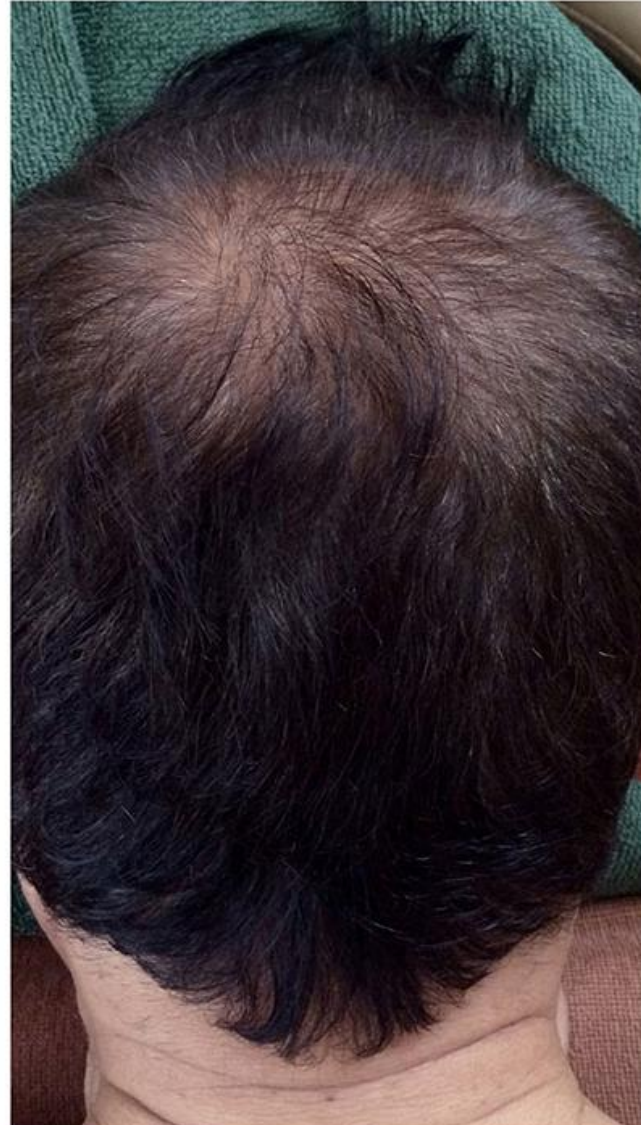Tinnitus:

➡ completely disappeared after 3 treatments

# Alopecia ameliorated unexpectedly!



6<sup>th</sup> Sep. 2014



17<sup>th</sup> May 2015



Therapist: Aki Kato (massage therapist)

Patient: female, 40 years old

Complaint: Psoriasis for 15 years

red inflamed patches and itchiness on:  
scalp, forehead, back, arms, thighs, around the ankles

Medication: Clobetasol propionate (**strongest steroid**) 3 times a day  
Tacalcitol hydrate (V.D derivative)

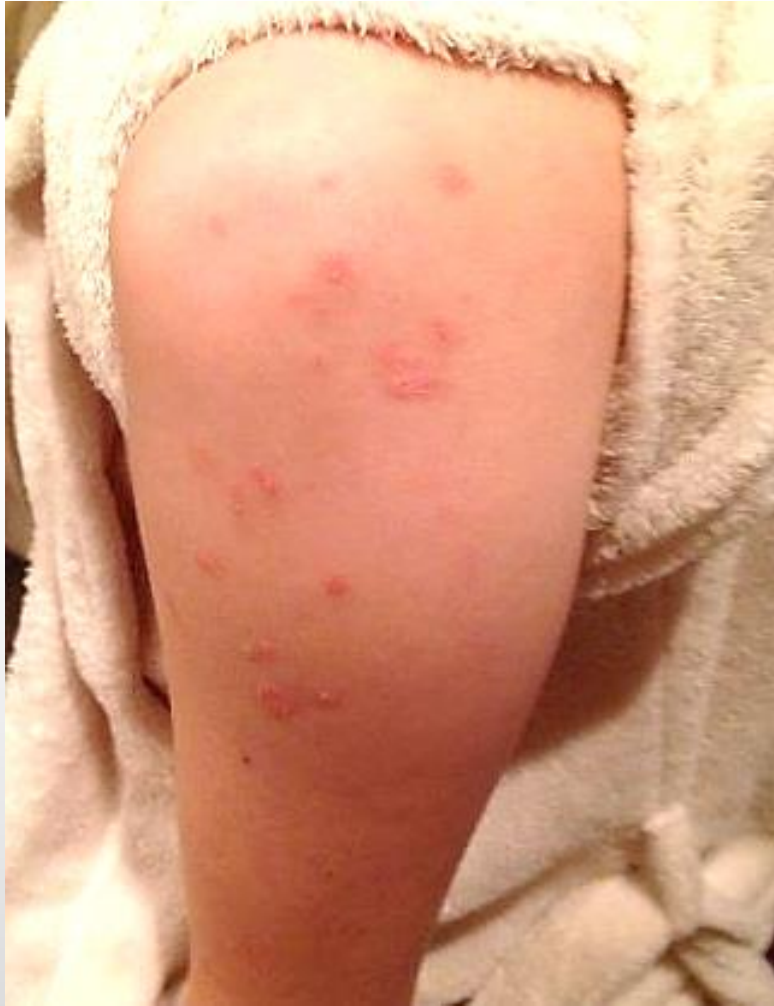Case study: started on 4<sup>th</sup> June 2014  
ended on 23<sup>rd</sup> July 2014  
14 treatments

Treated area: neck, face, head, abdomen, back, loin, buttocks,  
legs on average between 70 – 80 minutes per  
treatment.

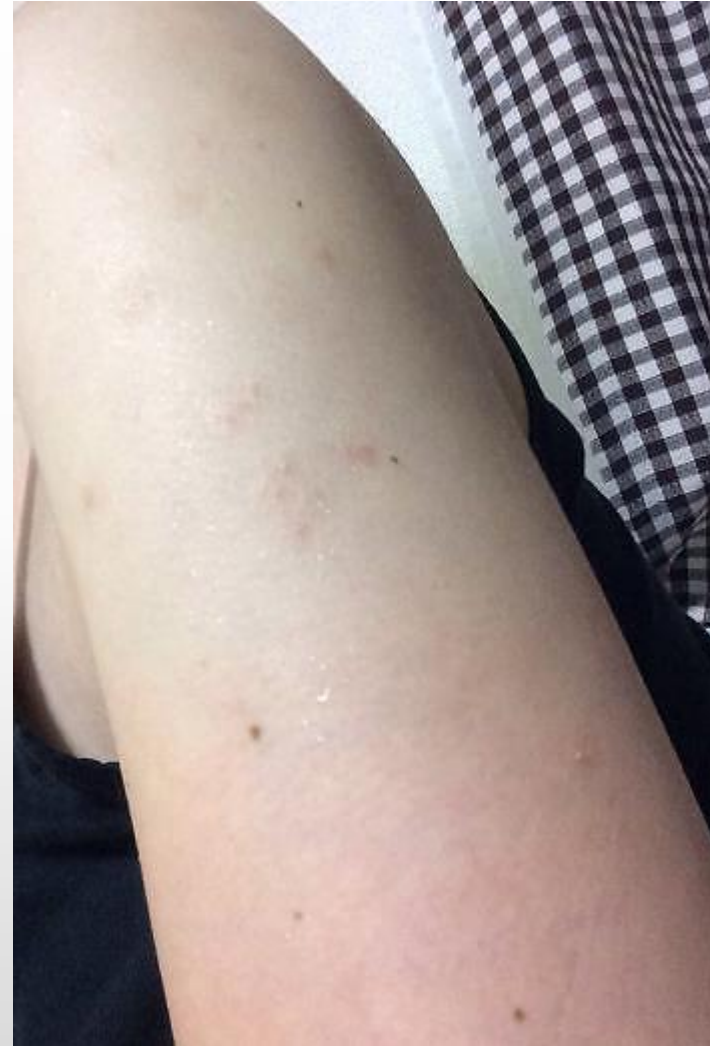The itchiness decreased from 8 to 0 (NRS) after the 5<sup>th</sup> treatment.  
Thereafter, it varied but was 3 at the end of the case study.

She stopped the steroid completely after the 5<sup>th</sup> treatments.

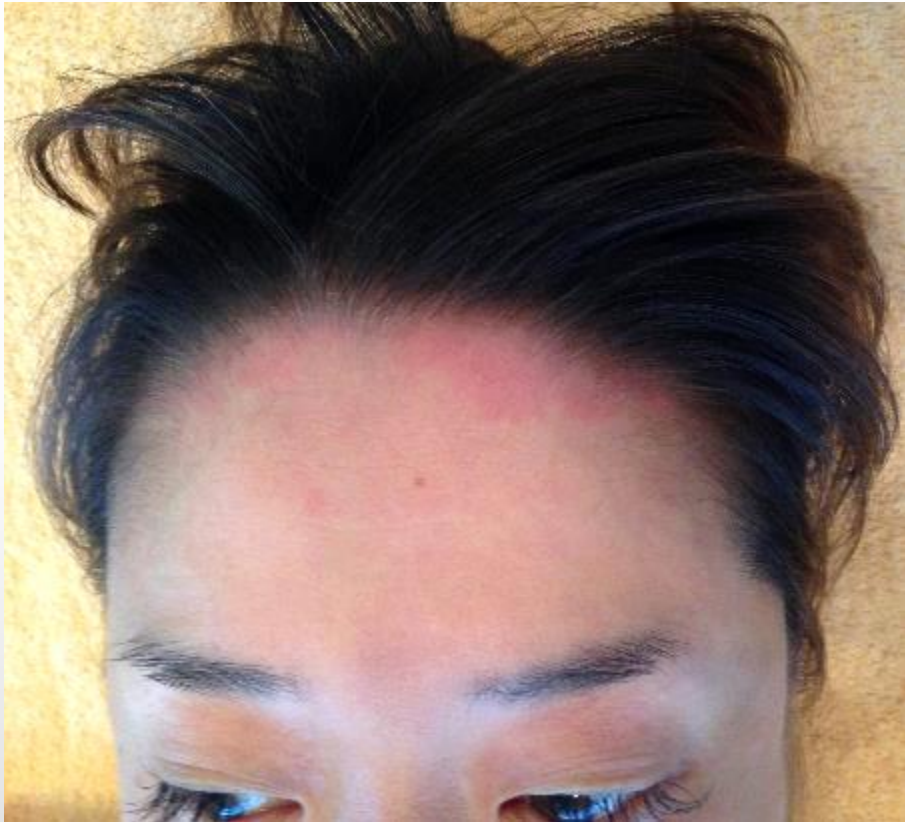The 8<sup>th</sup> treatment on 5<sup>th</sup> July



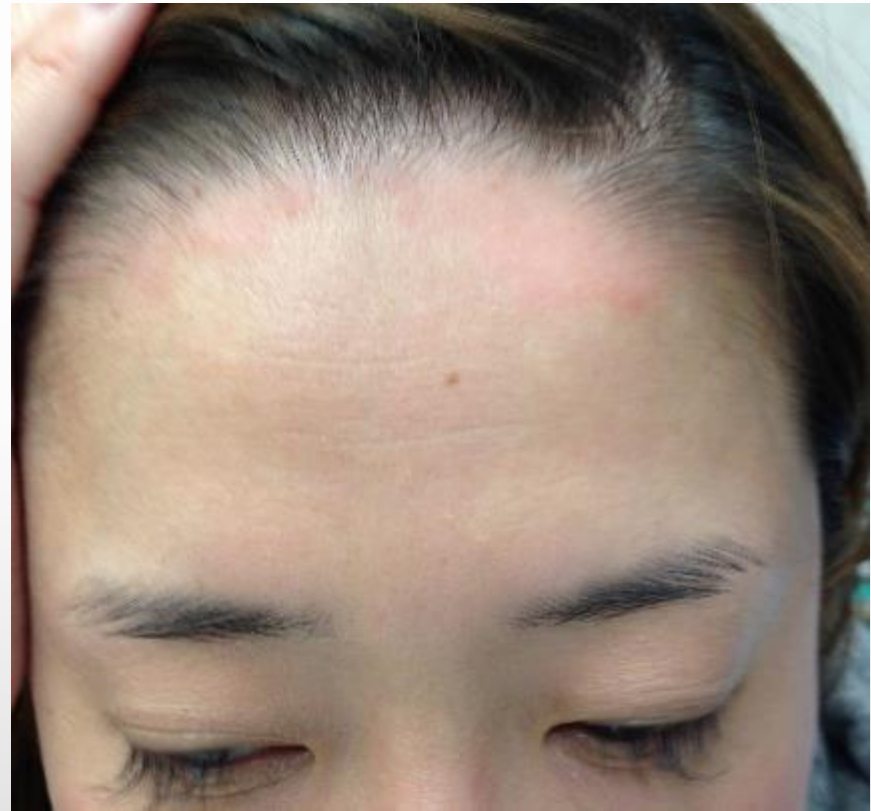The 14<sup>th</sup> treatment on 23<sup>rd</sup> July



The 6<sup>th</sup> treatment on 20<sup>th</sup> June

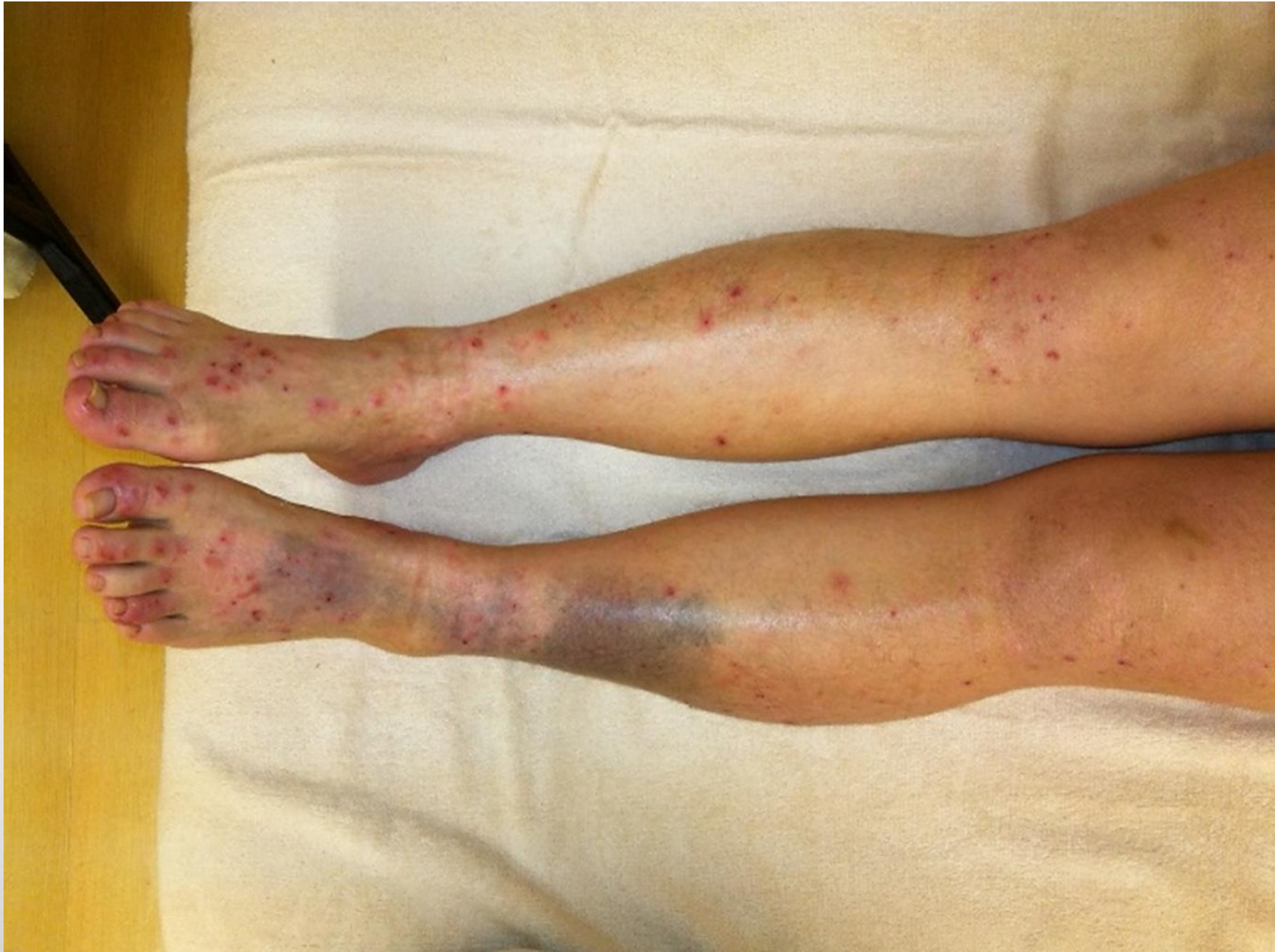

The 14<sup>th</sup> treatment on 23<sup>rd</sup> July



**Medical history:** The client had atopic dermatitis during childhood. It recurred at age 35 when she experienced a stressful event. She has been visiting a skin doctor every 3 weeks the past 7 years, but with little success.

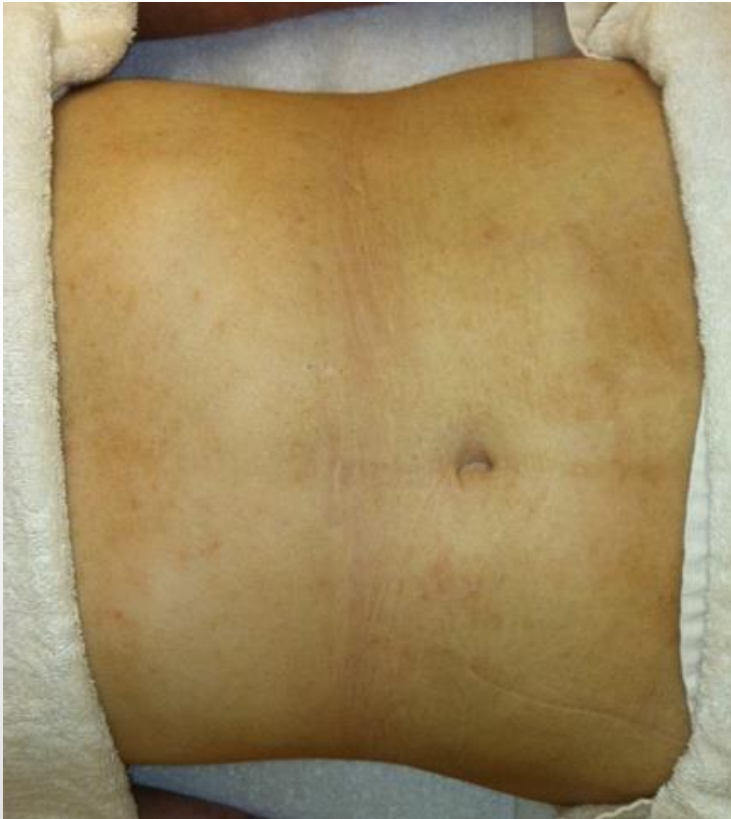
**Medication:** **Difluprednate (steroid: very strong)** application only on the hands and feet twice daily.  
**Hirudoid (heparinoid, moisturizer)** on the skin.  
**Zyrtec (anti-histamine).** Oral medication once a day



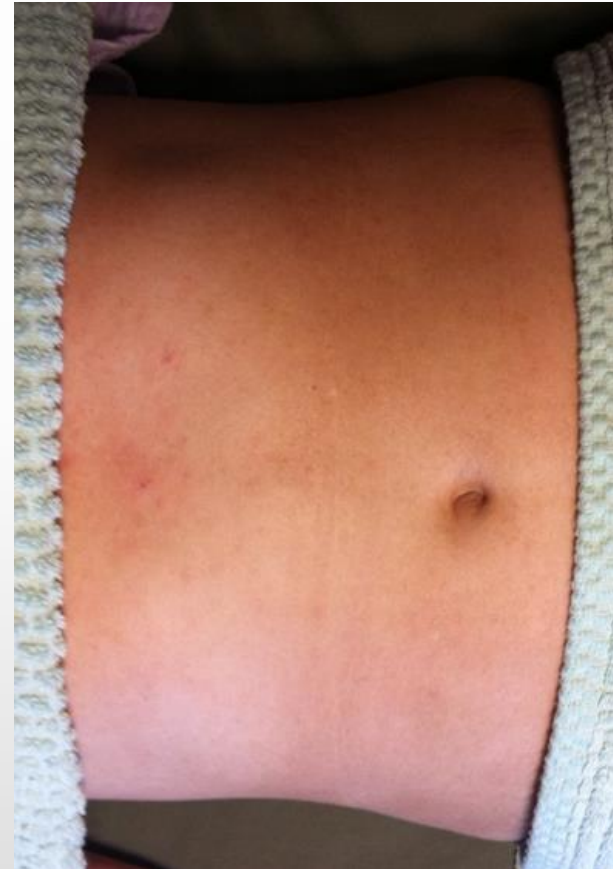Therapist: Kazue Gill

Client: female 42 years old with atopic dermatitis

Treated area: **neck, abdomen and legs**. 70 minutes to 90 minutes on average.



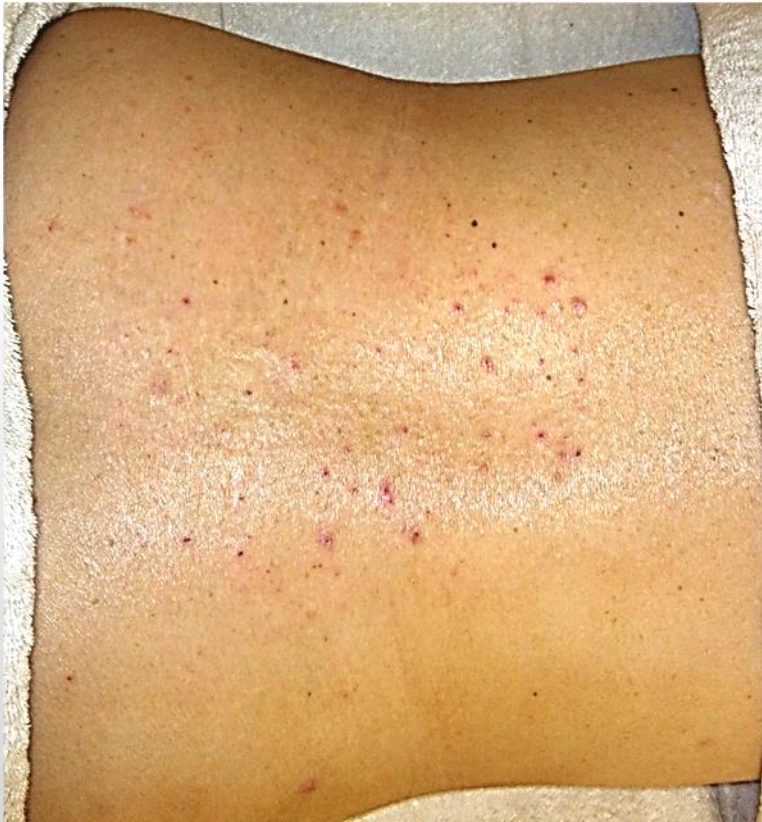3<sup>rd</sup> July 2012  
1<sup>st</sup> treatment



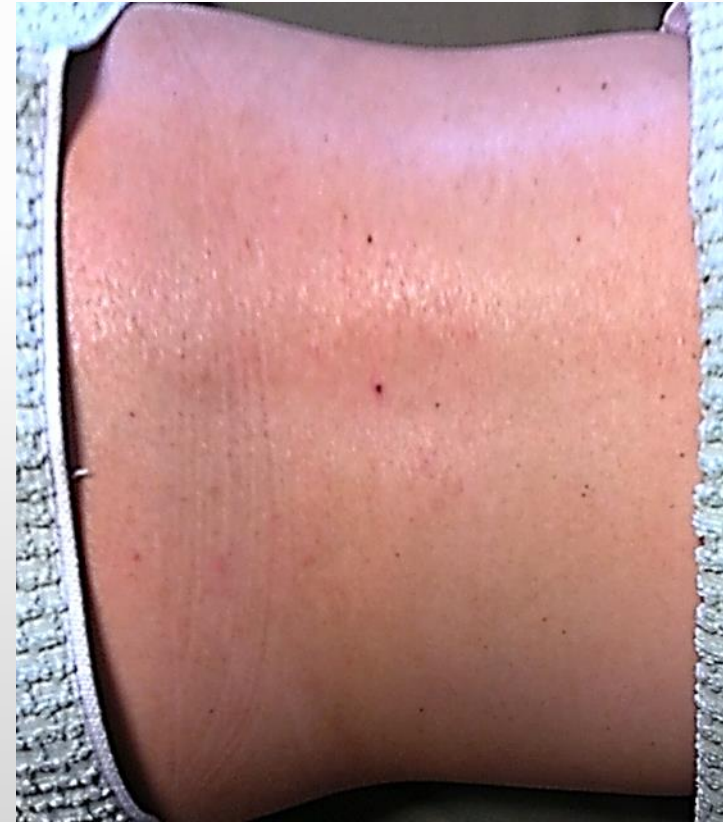
16th July 2012  
6<sup>th</sup> treatment

## Observation:

MLD is very useful as we do not necessarily need to touch the site of the problem, as its tissue cleansing and anti-inflammatory properties go beyond the parts of the body treated.



1<sup>st</sup> treatment 3<sup>rd</sup> July 2012



6<sup>th</sup> treatment 16<sup>th</sup> July 2012



**Gout:** Male, 48 years old.

Inflammation and pain in the right knee, ankle and MP joint on the 5<sup>th</sup> toe.

Medication: poultice containing loxoprofen

5 treatments in 16 days (90 minutes: neck, anterior and posterior legs )

Pain had disappeared immediately after every treatment, but returned after 2 days - 5 days.

During the treatment period, frequency of urination increased from 2 - to 3 times to 6 - 7 times /day.

Other conditions MLD has been used for:

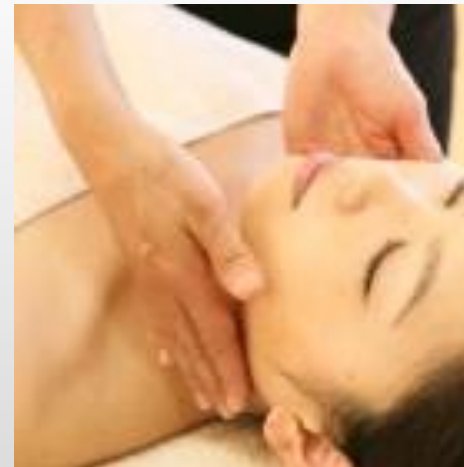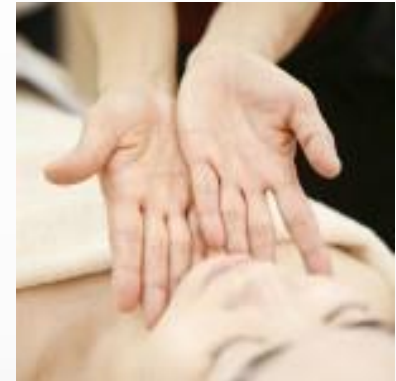Glaucoma,

Hydrocephalus,

Myasthenia gravis,

Otitis externa,

Ménière's disease



# Observation on the Effects of MLD by the MLD therapists in Japan:

- Marked improvement in menstrual cycle and pain.
- Amelioration of insomnia and constipation
- Higher energy level
  
- Reduction of unpleasant body odor through increased perspiration?)


Increased perspiration may be a result of the para-sympathetic N.S. stimulation?



- Increased urination frequency is often a sign that the conditions being treated with MLD will improve.
- If MLD is going to work for a particular condition, it would normally become obvious by 3rd or 4th treatment.
- With regular treatments, Pain-free period extends.

## Immediate post-treatment changes:

- Brighter vision
- Marked pain reduction
- Feeling relaxed and energized
- Feeling lighter



The more case studies we do with Vodder method of MLD,  
the more we find new uses for it!

*“ ...that this method could decongest the connective tissue,  
remove micro-edema in the connective tissue of the skin, and  
eradicate the source of many evils.”*

*Prof. Emil Vodder*

Quated by Prof. Hildegard Wittlinger in 'Dr. Vodder's Manual Lymph Drainage A Practical Guide'